



GLUCAGONOMA SYNDROME- A CASE REPORT

Jyotika Kalsy, **Anterpreet Kaur Arora, ***Sonney Singh Kapoor and *Sanjay Piplani**

*Department of Dermatology, Venerology and Leprosy. Govt Medical College, Amritsar

Department of Anatomy, *Department of Pediatrics, ****Department of Pathology
Sri Guru Ram Das Institute of Medical Sciences and Research, Vallah, Sri Amritsar.

ABSTRACT : The glucagonoma syndrome is characterized by dermatitis, glucose intolerance, hypoaminoacidemia, and hyperglucagonemia secondary to an alpha-cell tumor of the pancreas. The classical symptoms are associated with alpha-cell pancreatic islet cell tumor or 'glucagonoma'. Other clinical features include anemia, glossitis, and weight loss. A 65-year-old woman with the syndrome came for medical attention for a skin rash, glossitis, and weight loss. A skin biopsy was suggestive of necrolytic migratory erythema. Necrolytic migratory erythema is considered to be a paraneoplastic dermatosis. To our knowledge, it is rarely reported in the literature. Skin symptoms are important; often they are the clue to the diagnosis of glucagonoma syndrome. On ultrasound there was hypoechoic mass in the distal pancreas so she was advised CT scan of the mass. CT scan showed high density area 4.5 cms in diameter with calcification in the tail of the pancreas. She later on passed away because of late presentation, delayed diagnosis and delayed treatment. The diagnosis of necrolytic migratory erythema is a matter of great importance, since it might be an auxiliary tool for the early detection of glucagonoma.

Keywords : Glucagonoma, erythema, necrolytic, stomatitis.

INTRODUCTION

Glucagonoma syndrome was first described by Becker, Kahn, and Rothman in 1942. [1] Glucagonoma syndrome is an uncommon clinicopathologic entity. It is characterized by a glucagon-secreting tumor associated with hyperglucagonemia; necrolytic migratory erythema (NME); diabetes mellitus; hypoaminoacidemia; cheilosis; a normochromic, normocytic anemia; venous thrombosis; weight loss; and neuropsychiatric features. The finding of NME was once considered pathognomonic for glucagonoma syndrome. However, publications have reported that neither glucagonoma nor hyperglucagonemia is necessary for NME. [2] Pseudoglucagonoma syndrome refers to NME in the absence of a glucagon-secreting tumor. [3, 4] Since glucagonoma is slow growing tumor and good recovery is possible after surgical resection, an early diagnosis is mandatory. Therefore, a high degree of clinical suspicion is essential to diagnose this, otherwise fatal entity, early in its course. [5].

There are many theories about the pathogenesis of NME. The effects on the skin of the glucagonoma syndrome that result in NME may be due directly to glucagon itself or to other factors. The increased level of glucagon as a direct cause of NME is supported by some evidence: the demonstration in vitro that an increased level of glucagon yields greater amounts of epidermal arachidonic acid, which causes the inflammatory changes in the skin; [6] the cure of NME after surgical removal of the tumor, with consequent normalization of serum glucagon levels; [7, 8, 9, 10] and the remission of the rash after therapy with somatostatin analogue (octreotide), which is a potent inhibitor of glucagon release. [11, 12, 13]

Glucagonoma syndrome has been associated with tumors originating in alpha cells of the pancreas. These tumors demonstrate the typical characteristics of Islet cell tumors; they are usually encapsulated, firm nodules, varying in size from 2 cm up to 25 cm and occur most often in tail of the pancreas. [14] Age of onset is typically 50 to 60 years and no gender predilection has been observed. Malignancy, defined by presence of metastasis, is reported to be 60-70% but true malignancy rate is as high as 100 percent. Metastasis occurs with most frequency in liver and then in adjacent lymph nodes, bone, adrenals, kidney and lung. [15] Although good prognostic data is still lacking, the overall 5 years survival rate appears to be greater than 50%, and those with localized tumors have complete cure with total resection. [15]

CASE REPORT

A 65 years old female patient came in our skin out- patient department for medical attention and treatment of extensive skin rash over her body. She had history of on and off skin rash for the last one year but the present complaints were of two to three months duration. Superficial erosions with blistering at places started on the lower abdomen and groins with mild itching. (Figure 2) Later on the skin lesions progressed towards extremities and back. These changes were accompanied by angular stomatitis and painful glossitis. (Figure 1) She was diabetic for the last 7 years and at the time of presentation her diabetes was uncontrolled. She had lost 7.5 Kg weight in the past 3 months. She had already taken many treatments for the problem with partial relief so she was very upset that whether she will be alright or not and was on antidepressants.

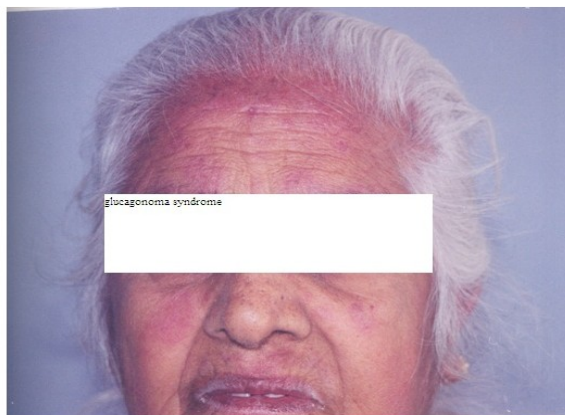

Figure 1 : Patient of Glucagonoma Syndrome showing Stomatitis

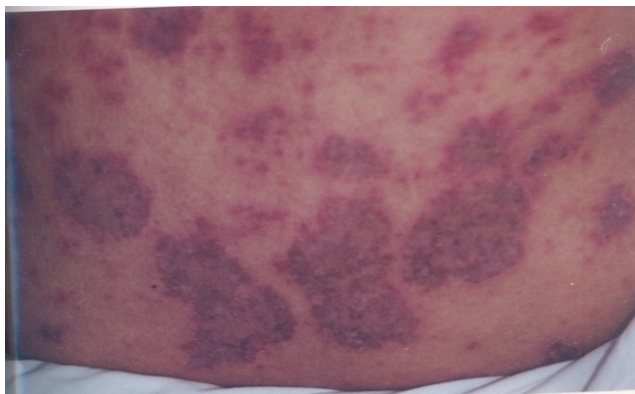

Figure 2 : Glucagonoma Syndrome-Skin Eruptions

After doing the thorough clinical examination following differentials were kept in mind were eczema, acrodermatitis, neuropathica, pellagra and necrolytic migratory erythema.

So she was advised a few laboratory tests for haemoglobin, peripheral blood film, TLC,DLC, FBS, LFT,RFT, Serum iron, B12, erythropoietin, reticulocyte levels, amino acid, zinc and essential fatty acid levels, (Table 1) skin biopsy of the rash, (Figure 3) ultrasound examination and hormonal assay.

When the patient reported back with the reports following positive findings were found as explained in the Table 1.

Table 1: Laboratory Tests

S.No	Lab Tests	Values
1	Haemoglobin	8.2gm%
2	TLC	12480 with more number of neutrophils
3	FBS	220mg%
4	Aminoacid, zinc	On the lower side
5	Essential fatty acid	On the lower side
6	S. glucagon levels	1380pg/ml (N 50-200pg/ml)

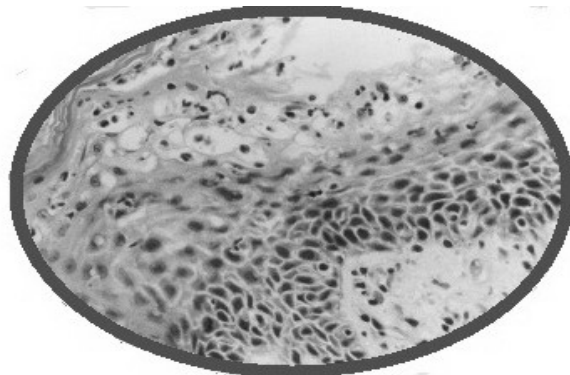


Figure 3. Histopathologic examination showing necrolysis of the upper epidermis with vacuolated keratinocytes along with neutrophils and lymphocytes at places in the epidermis and the dermis all changes consistent with NME.

On histopathologic examination there was necrolysis of the upper epidermis with vacuolated keratinocytes along with neutrophils and lymphocytes at places in the epidermis and the dermis. (Figure 3) all changes consistent with NME.

On ultrasound there was hypoechoic mass in the distal pancreas so she was advised CT scan of the mass. CT scan showed high density area 4.5 cm in diameter with calcification in the tail of the pancreas. Patient was put on haematinics, antibiotics, revised her diabetes medicine as advised by the physician, amino acid, zinc and essential fatty acid supplements were started. Hydrocortisone cream and mild emollients were given for topical application.

Regarding her CT scan surgical opinion was taken and was advised surgical removal of the mass and histopathologic examination. After this, the patient was lost to follow up. Then on tracing her on the given address it was learnt that she had her relatives in America where she was taken for further management. There inspite of successful surgical resection patient could not be saved may be due to the secondaries.

Had her diagnosis been made in time or had she reported in the department earlier one precious life would have been saved.

DISCUSSION

Becker described in 1942 a “diffuse progressive epidermal necrotic rash” associated with pancreatic neoplasm. [1] In 1966, McGravan et al. reported hyperglucagonemia in a patient with an eczematoid, erythematous rash, mild diabetes mellitus, anemia, and a glucagon-secreting alpha cell tumor of the pancreas. [16] Mallinson et al. defined the glucagonoma syndrome as presented in 9 patients with diabetes mellitus, anemia, weight loss, a distinctive rash referred as “necrolytic migratory erythema” (NME), and tumor of the islet cells of the pancreas. [17] Glossitis, stomatitis, cheilitis, diffuse alopecia, diarrhea, hypoaminoacidemia, increased incidence of thromboembolism, and psychiatric disturbances complete the glucagonoma syndrome. [18] Our patient had this rare and complete syndrome, with metastatic disease

at presentation, similar to what is reported in literature. [19]

Immunocytochemical findings show that glucagonoma has two distinct types: One associated with the glucagonoma syndrome, presented as a solitary and large tumor, with a solid microscopic pattern, low or lack of immunoreactivity for glucagon and high incidence of malignancy (60% of patients); the other one, not associated with glucagonoma syndrome, has tumors that are often multiple and small, have a gyriform microscopic pattern of growth, are strongly immunoreactive for glucagon, and are always benign [20, 21, 22].

The macroscopic and microscopic patterns of our patient’s tumor were those of a neuroendocrine neoplasm of pancreatic islet cells. [14] Unfortunately, in the present case, the diagnosis was confirmed at a late stage of the disease, and the ideal treatment was not instituted. The patient went to America for treatment and was expired there. This case illustrates the importance of early recognition of NME, with its distinctive clinical and histopathologic features, as well as signs and symptoms that compose the glucagonoma syndrome. These data suggest that the cause for the NME associated with glucagonoma is multifactorial, and it is likely that the postulated theories are not mutually exclusive.

CONCLUSION

Glucagonoma syndrome has only necrolytic migratory erythema, hyperglucagonaemia and islet cell tumor. Skin symptoms are important; often they are the clue to the diagnosis of glucagonoma syndrome. Since glucagonoma is slow growing tumor and good recovery is possible after surgical resection, an early diagnosis is mandatory. Therefore, a high degree of clinical suspicion is essential to diagnose this, otherwise fatal entity, early in its course.

REFERENCES

1. Becker SW, Kahn, Rothman S. Cutaneous manifestations of internal malignant tumours. *Arch Derm Syphilol.* 1942; 45; 1069-80.
2. Nakashima H, Komine M, Sasaki K, Mitsui H, Fujimoto M, Ihn H, et al. Necrolytic migratory erythema without glucagonoma in a patient with short bowel syndrome. *J Dermatol.* Aug 2006; 33(8):557-62.
3. Doyle JA, Schroeter AL, Rogers RS 3rd. Hyperglucagonaemia and necrolytic migratory erythema in cirrhosis--possible pseudoglucagonoma syndrome. *Br J Dermatol.* Nov 1979;101(5):581-7.
4. Echenique-Elizondo M, TuneuValls A, ElorzaOrúe JL, Martinez de Lizarduy I, Ibáñez Aguirre J. Glucagonoma and pseudoglucagonoma syndrome. *JOP.* Jul 2004;5(4):179-85.
5. Muhammad I, Riaz AK, Ghulam M. Review Article Glucagonoma syndrome. *Journal of Pakistan Association of Dermatologists.* 2009; 19: 106-108.
6. Peterson LL, Shaw JC, Acott KM. Glucagonoma syndrome: in vitro evidence that glucagon increases epidermal arachidonic acid. *J Am Acad Dermatol.* 1984; 2:468-473.
7. Abaira C, Debartolo M, Katzen R et al. Disappearance of glucagonoma rash after surgical resection, but not during dietary normalization of serum amino acids. *Am J Clin Nutr.* 1984; 39:351- 355.

8. Montenegro F, Lawrence GD, Macon W et al. Metastatic glucagonoma. Improvement after surgical debulking. *Am J Surg.* 1980; 139:424-427.
9. Reyes GJ, Holm A, Aldrete JS. Response of glucagonomas to surgical excision and chemotherapy. Report of two cases and review of the literature. *Am Surg.* 1989; 35:523-527.
10. Smith AP, Doolas A, Staren ED - Rapid resolution of necrolytic migratory erythema after glucagonoma resection. *J Surg Oncol* 1996;61:306-309.
11. Altimari AF, Bhoopalam N, Odorsio T. Use of somatostatin analog (SMS 201-995) in the glucagonoma syndrome. *Surgery.* 1986; 100:989-996.
12. Ching JL, Anderson JV, Willians SJ. Remission of symptoms during long term treatment of metastatic pancreatic endocrine tumours with long acting somatostatin analogue. *Br Med J.* 1986; 292:981-982.
13. Soga J, Yakuwa Y. Glucagonomas ,diabetic-dermatogenic syndrome (DDS). *J Hepatobiliary Pancreat Surg.* 1998; 5: 312-9.
14. Irwin M. Freedberg *et al.* Skin manifestations of alterations and disorders of the endocrine system, dermatology in general medicine. 2003, 1659-1660.
15. Mcgravan MH, Unger RH, Recant L et al. A glucagonsecreting alpha-cell carcinoma of the pancreas. *N Engl J Med.* 1966; 274:1408-1413.
16. Mallinson CN, Bloom SR, Warin AP et al. A glucagonoma syndrome. *Lancet.* 1974; 2:1-5.
17. Wermers RA, Vahab F, Wyne AG et al. The glucagonoma syndrome. *Medicine.* 1996; 75:53-63.
18. Montenegro RF, Samaan NA. Glucagonoma tumors and syndrome. *Curr Probl Cancer.* 1981; 6:3-54.
19. ROSAI J. Pancreas and ampullary region. In: ROSAI J. Ackerman's Surgical Pathology. 8th ed. St. Louis, Mosby, 1996. p. 990-999.
20. Hamid QA, Bishop AE, Sikri KL. Immunocytochemical characterization of 10 pancreatic tumours, associated with the glucagonoma syndrome, using antibodies to separate regions of the proglucagon molecule and other neuroendocrine markers. *Histopathology.* 1986;10:119-133.
21. Neves JM, Martins JEV, Gaburri AK. Glucagonoma: relato de caso e revisão de literatura. *Arq Gastroenterol.* 1996; 33:167-172.
22. Kheir SM, Omura EF, Grizzle WE. Histologic variation in the skin lesions of the glucagonoma syndrome. *Am J Surg Pathol.* 1986; 10(7):445-453.